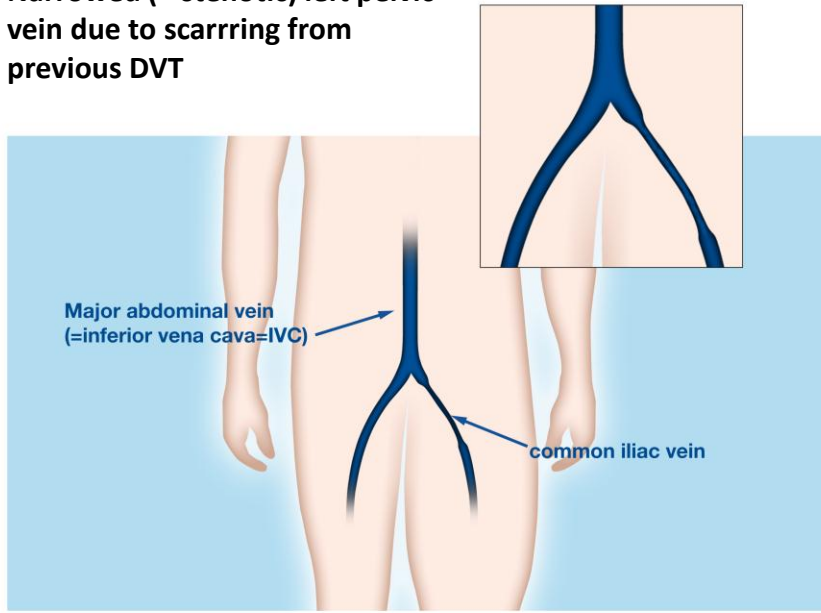


Narrowed (= stenotic) left pelvic vein due to scarring from previous DVT

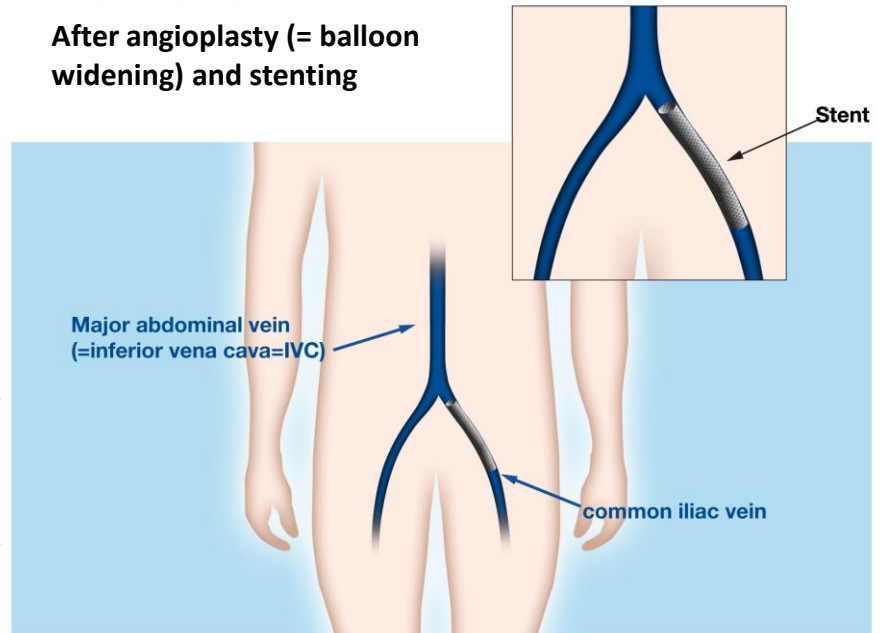
Graphic design: Jeff Harrison, Wilmington, NC



© Stephan Moll, M.D.

After angioplasty (= balloon widening) and stenting

Graphic design: Jeff Harrison, Wilmington, NC



© Stephan Moll, M.D.